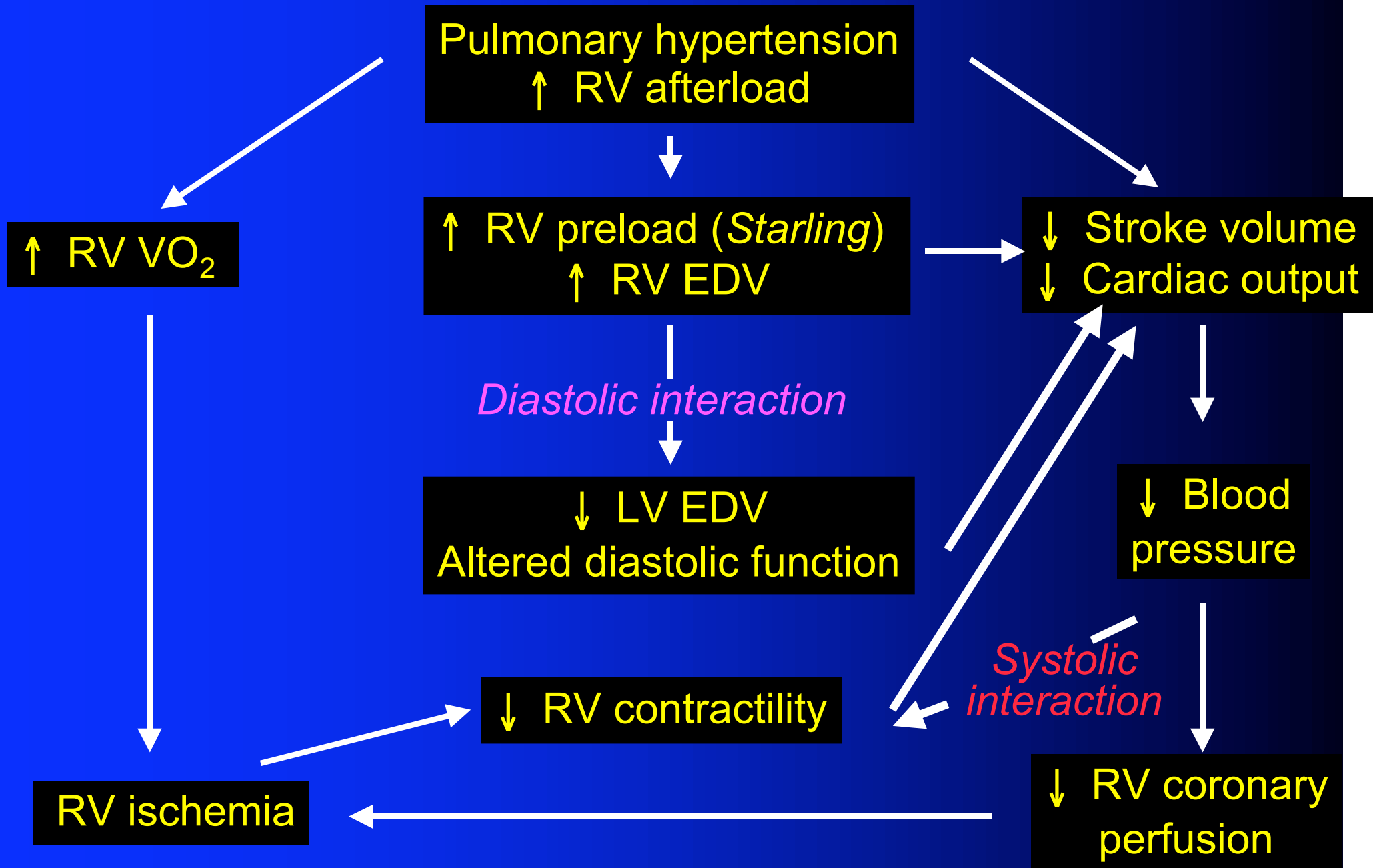
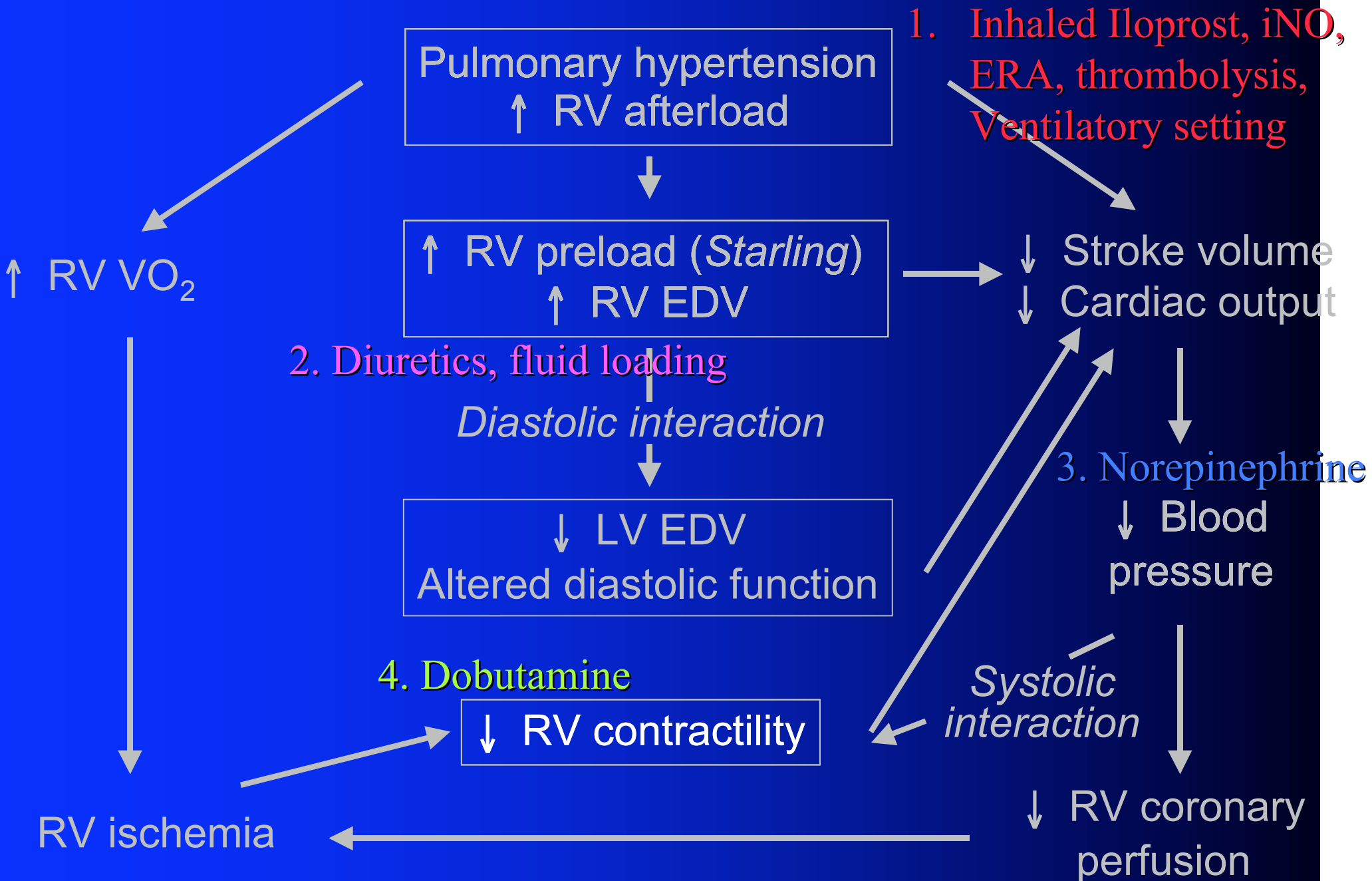


The acute right heart syndrome: ARHS

- Clinical presentation: systemic hypoperfusion (pale and clammy skin, confusion, chest pain, arrhythmia, ileus, oliguria, lactic acidosis) and systemic congestion (turgescient jugular veins, hepatomegaly, edema, ascites)
- Right atrial pressure $>$ left atrial pressure
- Dilated right heart chambers and septal shift, with eventually pericardial effusion, at echocardiography





Take home messages

1. Pulmonary hypertension: $P_{pa} > 25$ mmHg
Right heart failure: $P_{ra} > P_{wp}$
2. Importance of bedside echocardiography: RV and LV dimensions and contractility, septal shift, pulmonary flow, tricuspid regurgitant jets, LV diastolic function
3. Decrease RV afterload: iNO, Iloprost, fibrinolytic therapy, avoid pulmonary overinflation

Take home messages

4. Optimize RV filling: diuretics, fluid challenge, $P_{ra} < 10-12$ mmHg, echo control of septal shift and LV diastolic function
5. Restore systemic blood pressure, with systolic $P_{as} > 9-10$ cmHg: dopamine, norepinephrine
6. Increase RV contractility: dobutamine 5-10 $\mu\text{g}/\text{kg}/\text{min}$ to improve RV-arterial coupling, avoid β -blockers and inhaled anesthetics